

Dental care for your horse is vital to ensure both correct chewing and good digestion and also optimal comfort when being worked with a bit. We are often asked why it is necessary to rasp horses teeth when obviously no such service exists in the wild!

There are two main reason why our horses teeth require rasping;

1. Changes in dietary intake.

The wild horse grazes fibre of varying quality for 52 weeks of the year, so approximately 16 hours a day every day of the year are spent chewing long fibre. This, results in a very different tooth wear pattern especially when compared to the stabled horse who usually spends no more than a few hours a day eating fibres such as hay or haylage and obtains much of his energy from concentrate feeds. Concentrate feeds, required minimal chewing.

2. The use of a bit and the requirement to work in flexion.

Obviously putting a bit in a horse's mouth imposes upon us a duty to ensure the bit is comfortable against the teeth. The other factor that has a significant effect is the fact that we require our horse, when working in collection to have a vertical head position and the mouth closed. If you watch horses in the wild, or for that matter, racehorses, they gallop with the head in a horizontal head position and very often the mouth slightly open. This has nothing to do with breathing as horses are obligatory nose breathers, i.e. they can only breath through their noses via nostrils. For a horse to have its head in a vertical position, the lower jaw has to move down slightly relative to the upper jaw. For this to happen it must be possible for the abutting rows of teeth of the upper and lower jaw to be able to move smoothly against each other. If there are steps or ridges on the teeth, these will lock against the opposing tooth and the only way the horse can achieve the vertical head position is by opening its mouth to separate the rows of teeth.

Of course when this happens the first thing we tend to do is fit a noseband to prevent the horse from opening its mouth! Thus if you feel you are getting resistance when asking your horse to go in collection and you have a tightly fitted noseband it may be worth loosening the noseband to see if you get improvement in the way the horse is going. This may well alert you to the root cause, being teeth rather than schooling. The other impact of the vertical head position and the bit is that the cheeks are pulled in towards the outside of the upper teeth and the tongue is flattened outwards towards the inside of the lower teeth. The significance of this lies in the fact that the horse's upper jaw is always wider than the lower jaw by about a third. Thus horses do not chew up and down but chew crossways in a circular motion. This results in the formation of enamel points on the outside of the upper teeth and inside of the lower teeth—just the areas which the soft tissues of the cheek and tongue will be pressed against. Thus we can see the reasons of requiring regular dental care for our horses are predominately man-made.

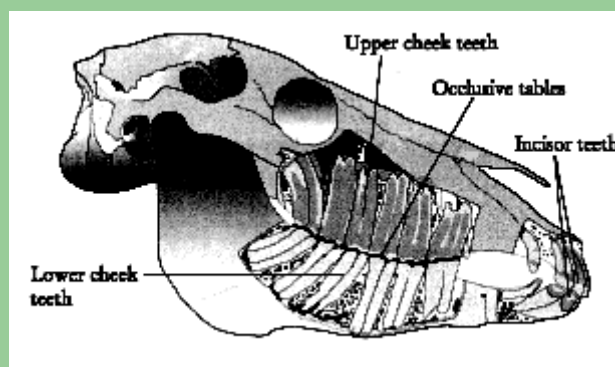
What dental care does your horse require?

The amount of dental work needed by a horse will depend on the confirmation of its jaw and the degree of collection the horse is required to work in. If a horse has normal jaw confirmation, has an adequate amount of fibre in its diet and is regularly ridden, dental attention is probably required once a year. A good time to do this is at your horse's annual vaccination.

To correctly rasp a horse's teeth it is first necessary to examine the teeth, cheek, gums and tongue both by feel and eye to check for existing problems which should then be recorded on a pre-prepared dental chart. To carry out an adequate examination, we use a Haussmans gag and head torch which enables us to access all areas of the mouth. The better quality rasp blades that you use when rasping a horse's teeth result in not only a better job, but importantly a quicker job.

We use high quality tungsten carbide blades, which are changed regularly to ensure at all times that they are sharp. This means that enamel points and hooks on the teeth are removed with fewer strokes compared to using cheaper carbide chip or old blunt blades where many more strokes of the rasp will be required to achieve the same effect. The reason it is necessary to work efficiently using good quality kit is that it keeps the amount of time the horse is required to stand with its mouth open down to a minimum. We all know from going to the dentist ourselves that sitting with your mouth wide open is not a comfortable experience, never mind the problems of trying to chat at the same time.

When it is necessary for the horse to have its mouth held open for prolonged period, e.g. for tooth extractions or for power tool work to be carried out due to dental overgrowth, then the horse should be given regular rest periods when the gag is released and the jaw muscle rested. It is incumbent on us when doing horse's teeth to work quickly and efficiently. As well as sharp blades, a variety of rasps are required to ensure that all teeth in the mouth can be accessed. Rasps of different lengths, thickness and angle are required to ensure any irregularities on the teeth can be easily reached and the sharp areas reduced. Below is a picture showing just how far back in your horse's mouth the cheek teeth extend and just how many teeth there are.



The need for mechanical or power tools

Power tools such as a dremel, which is a rotary burr, are used when there is a need to remove crown of tooth to correct a dental problem in the horse. Such problems may occur because of conformational abnormalities in the jaw, e.g. a parrot mouth. If the upper incisors are overshot, so will the cheek teeth be. Thus, the first upper cheek teeth will develop large hooks as will the last lower cheek teeth. If such problems are not noted early on and the hooks are allowed to grow large, they can only be removed using a power tool. The hooks will obviously continue to grow but if the teeth are rasped regularly, e.g. 2-3 times a year, the amount of growth is minimal such that a rasp will be adequate to remove the over growth at least for a time. Power tools should be used with care as it is possible to cause thermal damage to the teeth if they are used at too high a speed. If they are used too aggressively they can expose the pulp or sensitive area of the tooth. Power tools are very useful for correcting some serious dental abnormalities in horses, many of which may have been present for some time and correcting them can make a real difference to the horses comfort day in and day out.

What constitutes bad equine dental care.

Many of the developments in equine dentistry were brought over to the UK from work done in the USA, especially in the early 1990's. Since that time the Americans have altered their approach to tooth rasping after veterinary research into the implications of dental work going on was finally carried out. The "fashion" was to rasp all the teeth completely smooth on all their surfaces which, theoretically, sounds like a good idea. However, as so often nature is cleverer than we give her credit for. The naturally occurring ridges on a horse's teeth are important for saliva flow pattern through the mouth. It is saliva that cleans the teeth. Thus interfering with its flow around the teeth causes an increase in gingivitis (gum inflammation) and gum recession and shortens the life of the tooth. Therefore, while it is important to remove all enamel points that may press on the soft tissues of the mouth, a transverse ridge pattern should always remain post rasping.

Horses' teeth grow throughout life. Young horses have very long tooth roots and, as teeth are worn down, they continue to erupt to maintain a grinding surface and the tooth root shortens. In old age, the tooth may be so short that the tooth drops out and is no more. The horse's teeth continue to erupt throughout life at a steady rate provided they are abutting the teeth on the opposing arcade. If the teeth are over rasped and the height of the tooth reduced so they no longer oppose, the lack of counter pressure will cause the teeth to "super erupt" until they oppose again. This is effectively shortening the life of the tooth as you have artificially increased its rate of eruption, thus reducing the size of the reserve root.

With both the above conditions it can take some time (often years) before your sins will catch up with you. During this time the horse may even have changed hands and thus no one is really sure about the horse's previous dental history. It is very difficult to evaluate dental work as an owner as much of it is unseen.



EQUINE DENTISTRY

Performance floating

The principles of a well rasped mouth are the same whatever the age or type of the horse. However, there are certain things that can be done which are particularly relevant to the performance or competition horse. The creation of “bit seats” on the first cheek teeth helps the bit sit more comfortably in the horse’s mouth. To create a bit seat, the first cheek teeth are rounded at their front edges. However, care should be taken not to over exaggerate this rounding as it can effect the grinding surface of the tooth and tooth eruption if it is overdone. Opinions do vary as to the effectiveness of the bit seats and often to create a true bit seat, power tools are needed. In such an event great care should be taken because it is very easy to over do it when using power tools especially in unqualified hands.

It is also true to say that some horses tolerate the development of enamel points on their teeth much better than others. Thus there is no set interval advisable for teeth rasping, it will depend on your individual horse’s jaw conformation and the work he is required to do.

Should you have any queries or would like to know more, please contact us in the equine office.